Dr. Jonathan L. Ferencz, D.D.S.
NYC Prosthodontics

Anterior aesthetic veneers using a digital workflow

Solutions featured:

3Shape TRIOS® intraoral scanner
3Shape Dental System

3shape

Fig. 1

Fig. 2

Case information

A 70-year-old patient presented with a diastema and failed composite restorations to correct excessive tooth wear and incisal chipping on teeth #8 and #9. (Fig. 1 + 2)

A retracted digital scan (Fig. 3 + 4) of the patient's preoperative condition was taken and sent to the laboratory and uploaded into CAD software for a diagnostic wax-up of the proposed final case outcome.

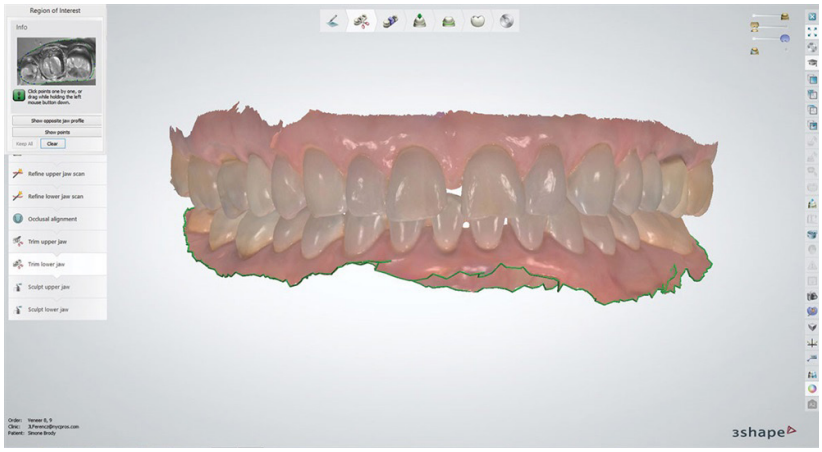

Fig. 3

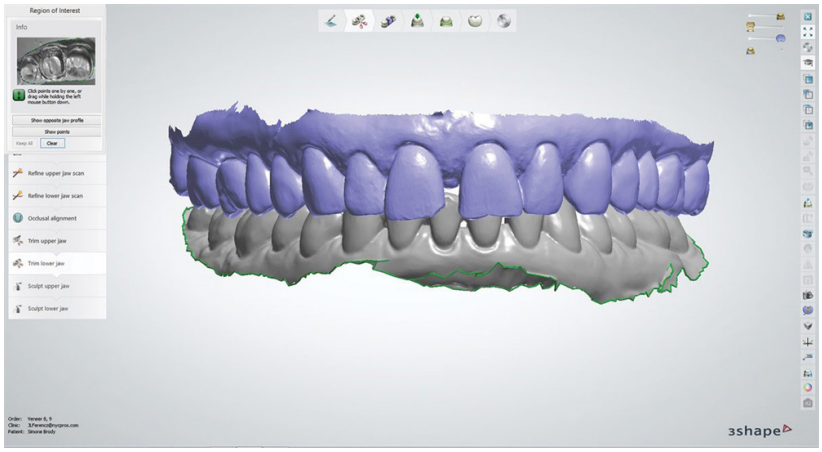

Fig. 4

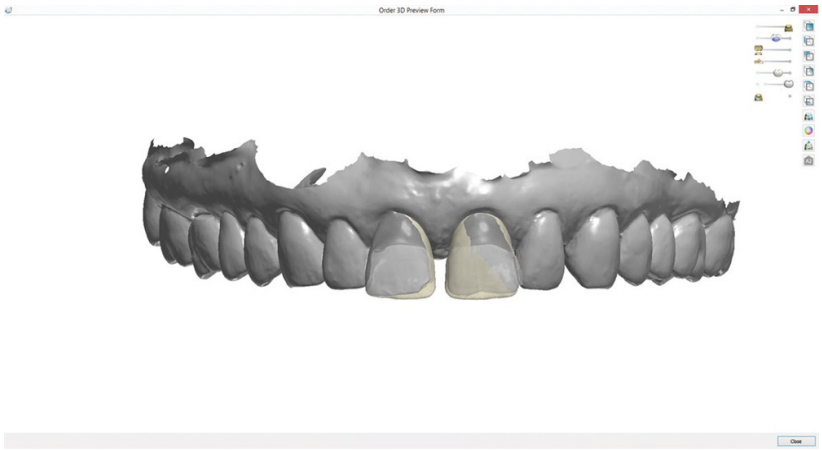

Fig. 5

Within minutes, the technician proposed two solutions for the patient to view onscreen.

One solution proposed lengthening the teeth slightly and fabricating veneers that would close the diastema. The second solution proposed keeping the diastema and repairing the two anterior centrals with highly aesthetic veneers. (Fig. 5)

After viewing the virtual proposals, the patient expressed that she was less concerned by the aesthetics of her diastema. She declined the proposed design for tooth lengthening and diastema closure and approved the proposed design for two single central veneers.

Fig. 6

Treatment Plan

A clinical appointment was scheduled one week after the initial presentation for tooth preparation and provisionalization.

Before the first scheduled clinical appointment, the laboratory used CAD/CAM technology to design the temporaries and the final restorations in exact accordance to the patient-approved 3D virtual diagnostic wax-up of the final case outcome.

A 3D-printed model of the approved smile design (Figs. 6 + 7) was used to produce an analog silicone putty reduction matrix chairside. (Fig. 8) This was the only analog process in an otherwise digital workflow.

Fig. 7

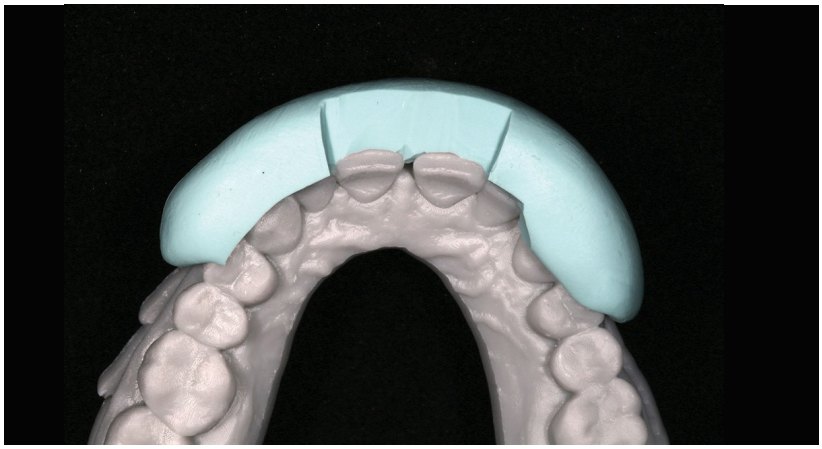

Fig. 8

Fig. 9

A reduction guide is created from a digital diagnostic design, instead of manually from an analog wax-up, as in a conventional workflow. (Fig. 9)

Fig. 10

The patient's prepared teeth. (Fig. 10)

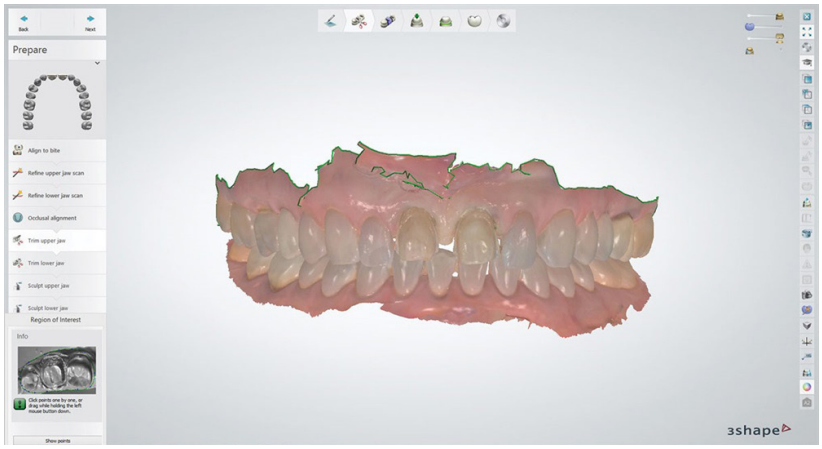

Fig. 11

The prepared teeth were then scanned using an intraoral scanner (Fig. 11) and the scans were uploaded to the laboratory for final design of the provisionals and final restorations. (Fig. 12)

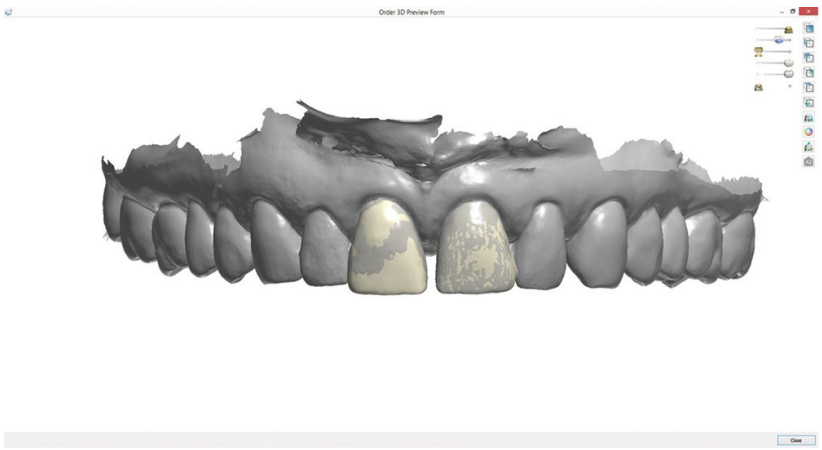

Fig. 12

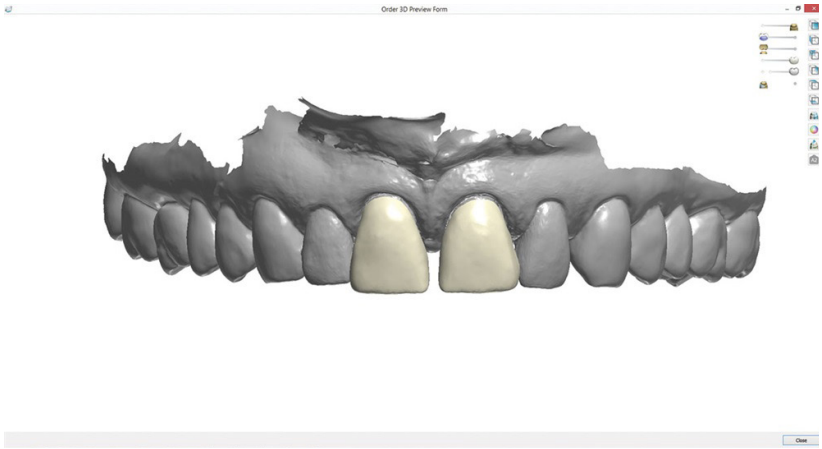

Fig. 13

Fig. 14

Fig. 15

Case information

While the patient waited, the laboratory milled the tooth-colored temporaries from polymethyl methacrylate (PMMA) on an Ivoclar Vivadent PrograMill PM7 mill. The PMMA veneers were delivered and tried in for patient approval. Once the patient approved the aesthetics and fit chairside, we recommended the provisionals be worn for at least a couple of days to test the fit and function before we move on to milling the final definitive veneers. When the patient calls approving the fit and function, we can confidently move forward with milling the final restorations using the same digital file used to fabricate the temporaries (Fig. 13). In this case, the final veneers were milled from IPS E.max CAD on our PrograMill One mill by Ivoclar Vivadent, which is well suited for producing thin margins and thin 0.5mm monolithic veneers. The final veneers are monolithic with no cutback, thus retaining the material's 500MPa strength.

At the second clinical appointment, the provisionals were removed, the preparations cleaned, and the final veneers seated using Variolink Esthetic dual-cure composite luting cement. (Fig. 14 + 15) Patient satisfaction was high because no adjustments were needed, and the final restorations precisely duplicated the proposed and approved provisional restorations.

Comments

Digital technologies have significantly streamlined the workflow and eliminated the guesswork from the time-intensive analog processes with intraoral scanning technology and CAD smile design software. However, for veneer cases, the one missing link in today's digital workflow is the creation and delivery of a reduction guide that exactly duplicates the digital plan.

In an analog workflow environment, the reduction guide fabrication would typically start with a traditional impression. The impression would then be sent to the laboratory with instructions for design and fabrication of a diagnostic wax-up for patient approval of the final treatment outcome. If the patient approves the wax-up of the final design, the laboratory creates a putty impression of the wax-up for the dentist to use as a reduction guide during the tooth preparation appointment. Should the patient demand changes to the wax-up smile design, the dentist would communicate those requests to the laboratory and a new diagnostic wax-up and reduction guide would be created, with associated increased costs, patient visits and chair time.

The risks of working in the aesthetic zone without a reduction guide are either under- or overprepping the natural teeth. If the teeth are underprepared, the final veneers will be overcontoured to hide underlying stump shades. If the teeth are overprepared and enamel removed, the veneers' bond strength may be significantly compromised. In either case, the provisionals and final restorations may not accurately match the digital diagnostic wax-up and the dentist risks patient rejection of the final restorations, resulting in a remake.

One solution would be a virtual 3D-printed reduction guide that is delivered with the 3D-printed diagnostic wax-up model. Another solution would be to design the intraoral scanner software with the ability to compare the preparation to the virtual diagnostic wax-up and identify areas that are underprepared.

In the future, I am confident that CAD software will address the need for a digitally driven 3D reduction guide.

Conclusion

Digital technologies eliminate the guesswork and inherent inaccuracies of analog processes and improve clinical workflows and efficiencies.

For example, intraoral scanners eliminate the need for physical impressions and the inaccuracies inherent in the handling and processing of impression material. The digital impression scan is uploaded to the dental laboratory and in conjunction with CAD software is used to create a virtual digital diagnostic wax-up of the proposed case outcome.

In terms of the workflow, from approval of the virtual treatment design and milled provisionals to delivery and seating of the final veneers, the precision of CAD/CAM technologies ensures exact duplication from start to finish. This level of predictability reduces clinical stress and anxiety, eliminates remakes and increases practice profitability.

About Dr. Jonathan Ferencz

Dr. Jonathan Ferencz graduated from Rensselaer Polytechnic Institute with a degree in biology in 1967 and the New York University College of Dentistry in 1971. He subsequently opened a private practice in midtown Manhattan and enrolled in the part-time postgraduate program in prosthodontics. In 1984, he established the first honors programs in prosthodontics for fourth-year students at NYU. In 1990, Ferencz became clinical professor of postgraduate prosthodontics, and was certified by the American Board of Prosthodontics in 1998. In addition to numerous fellowships, memberships and published materials, Ferencz is a clinical professor of prosthodontics at the NYU College of Dentistry, University of Pennsylvania and the Columbia University School of Dental Medicine. He also is a consultant for Henry Schein, 3Shape and Ivoclar Vivadent, focused on dental materials and emerging technologies used in CAD/CAM and other digital dental applications.

About 3Shape

3Shape is changing dentistry together with dental professionals across the world by developing innovations that provide superior dental care for patients. Our portfolio of 3D scanners and CAD/CAM software solutions includes the multiple award-winning 3Shape TRIOS® intraoral scanner, the upcoming 3Shape X1® CBCT scanner, as well as market-leading scanning and design software solutions for both dental practices and labs.

Two graduate students founded 3Shape in Denmark's capital in the year 2000. Today, 3Shape has over 1,500 employees serving customers in over 100 countries from an ever-growing number of 3Shape offices around the world. 3Shape's products and innovations continue to challenge traditional methods, enabling dental professionals to treat more patients more effectively.